

The Natural Angle

VOLUME 15: ISSUE 1

THIS NEWSLETTER PUBLISHED FOR MARÉCHALERIE BROMONT INC

Farriery for the Club Foot

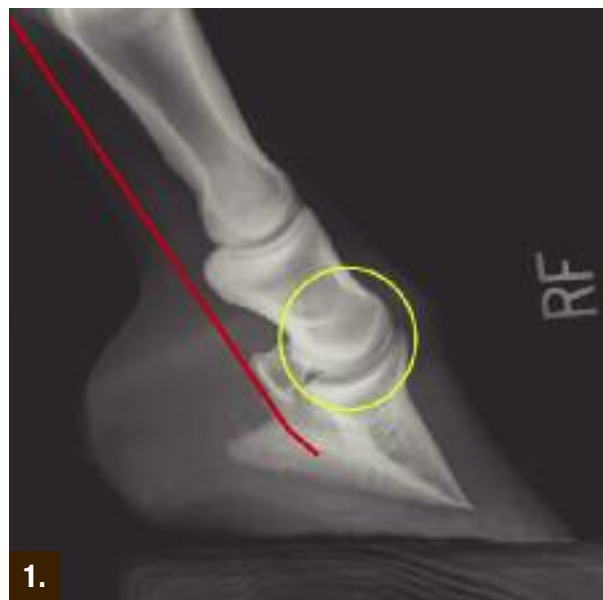
by Stephen E. O'Grady, DVM, MRCVS

Farriery for horses with a club foot conformation can present a challenge for both veterinarians and farriers. A true club foot can be defined as an upright conformation of the foot associated with a flexural deformity of the distal interphalangeal joint (DIPJ)¹⁻⁵. Grossly, the dorsal hoof wall angle is upright or steep accompanied by a broken forward foot-pastern axis. A flexural deformity of the DIPJ can be defined as a shortening of the musculotendinous unit of the deep digital flexor tendon (DDFT) that results in hyper flexion of the joint¹⁻⁵ (Figure 1). Flexural deformities are responsible for the club foot conformation seen in mature horses. Flexural deformities have been traditionally referred to as “contracted tendons” but this term is a misnomer as the primary defect appears to be a shortening of the entire musculotendinous unit rather than just a shortening of the tendon structure, thus making “flexural deformity” the preferred descriptive term¹. Shortening of the

musculotendinous unit produces a structure of insufficient length to allow normal alignment of the distal phalanx (P3) relative to the middle phalanx, resulting in variable clinical signs ranging from an upright hoof angle to a club foot. Flexural deformities have been reported as a cause of decreased athletic performance and chronic, low-grade lameness in the mature horse.

Anatomy Review

A review of the relevant anatomy is helpful to understand the biomechanics. The muscle bellies of the deep digital flexor tendon lie directly on the caudal aspect of the radius and are covered by the muscle bellies of the superficial digital flexor tendon (SDFT) and the flexors of the carpus. The deep digital flexor muscle consists of three muscle bellies which form a common tendon proximal to the carpus. This DDFT, along with the SDFT, passes through the carpal canal and continues down the palmar aspect of the third metacarpal bone. Below the fetlock, at the level of the middle phalanx, the DDFT passes between the medial and lateral branches of the SDFT, continues distally and inserts on the flexor surface of the distal phalanx (P3). A strong tendinous band known as the accessory ligament of the DDFT (AL-DDFT) originates from the deep palmar carpal ligament and fuses with the deep digital flexor tendon at the middle of the metacarpus



1.

Figure 1. Radiograph shows a moderate flexural deformity (yellow circle) involving the DIPJ in a horse with a club foot. The flexural deformity is caused by a shortened DDF muscle tendon unit (red line)

Continued on page 2

Continued from page 1

(Figure 2). The design and function of the anatomical structures is such that any prolonged shortening of the musculotendinous unit affects the position of the DIPJ. The palmar surface of the distal phalanx is pulled palmarly by this shortened musculotendinous unit, placing the DIP joint in a flexed position. The alignment of the bone within the hoof capsule remains constant while the hoof capsule is pulled with the distal phalanx. The flexed position of the DIPJ combined with the altered load on the foot leads to a rapid distortion of the hoof capsule and thus the club foot conformation.

Flexural deformities in the mature horse

Club foot - a hoof capsule distortion

There is minimal information in the veterinary literature regarding the management of a mature horse with a club foot. Farriery to maintain or improve the club foot is often empirical and based on past experience. The altered biomechanics of the foot result in an increased load (i.e., weight-bearing) being placed on the dorsal section of the foot leading to decreased sole growth, sole bruising, a shortened stride on the affected limb, and various degrees of lameness and poor performance. To apply the appropriate farriery, understanding the proposed mechanism leading to the club foot conformation is helpful. When a flexural deformity is present, the musculotendinous unit is shortened, the degree of which can be determined by the amount of flexion in the DIP joint. This causes a disparity of hoof wall growth, with more growth at the heel than at the toe to compensate for the decreased

length of the musculotendinous structures. The frog will generally recede below the hoof wall due to the excessive hoof wall growth at the heels so that the energy of impact is assumed entirely by the hoof wall, bypassing the deformable soft tissue structures and transferring the load directly onto the bones of the digit through the laminar interface. The flexural deformity, combined with the excess hoof wall growth at the heels, places the DIPJ in flexion and the distal phalanx in an abnormal alignment relative to the digit; this promotes toe-first landing and therefore excessive load on the dorsal section of the DIP joint and hoof capsule.

Hoof abnormalities associated with a club foot conformation are thin flat soles, concavity of the dorsal hoof wall, poor hoof wall consistency, especially at the toe, toe cracks, hoof wall separation, and so-called "white line disease"⁶ (Figure 3a & 3b). Injuries associated with a high hoof angle are thought to include inflammation of the DIPJ due to abnormal loading of the joint, sole bruising, and increased strain on the suspensory ligaments of the navicular bone^{6,7}.

Therapeutic Farriery

Therapeutic farriery forms the mainstay of treatment for club feet. Farriery should be based on principles rather than a particular method, and the principles remain the same regardless of the severity of the flexural deformity²⁻⁵. The principles are to achieve normal alignment between the proximal, middle, and distal phalanges and thus normal orientation and loading of the distal phalanx relative to the ground. Trimming and shoeing is aimed at removing weight-bearing from the toe and dorsal aspect of

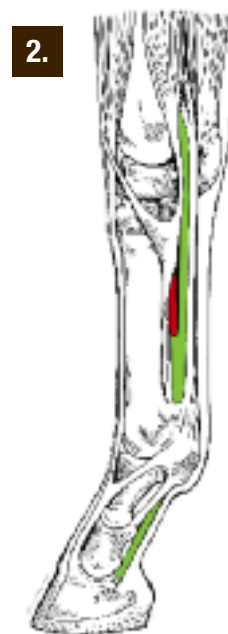


Figure 2. Illustration shows the structures involved in a flexural deformity of the DIP joint. Note the close association between the AL-DDFT (red line) and the DDFT (green line).



Figure 3a. A grade 3 club foot on a mature horse. Note the broken forward hoof-pastern axis, the concavity in the dorsal hoof wall, the disparity in hoof wall growth between the toe and the heel and the poor hoof wall consistency distally. **Figure 3b.** Shows the frog to be receded between the hoof wall and a sheared heel.

KERCKHAERT STANDARD SERIES Designed for Versatility

The Kerckhaert Standard Series meet the needs of a wide variety of general purpose riding activities.

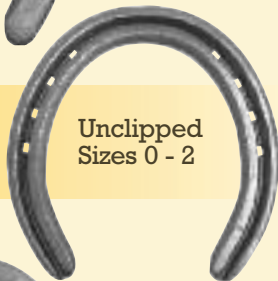These versatile shoes are easily shaped to fit the front or hind foot, without the pointed toe shape of other brands that makes fitting difficult.



Unclipped
Sizes 00 - 3

STANDARD

STANDARD
RIM



Unclipped
Sizes 0 - 2



Unclipped
Sizes 00 - 3

STANDARD
EXTRA

Kerckhaert Standard series are punched for Liberty 5 City or 5 Slim.



the distal phalanx and re-establishing weight-bearing to the entire solar surface of the distal phalanx and the corresponding hoof capsule. Historically, farriers have been taught to trim (lower) the heels to correct the distorted hoof capsule and promote weight-bearing in the heel area, but this method comes with a price. As the severity of the flexural deformity increases, so too does the shortening of the musculotendonous unit; therefore, lowering the heels will consequently increase the tension within the musculotendonous unit, and these stresses may lead to irresolvable tearing of the dorsal lamellae, widening of the sole-wall junction similar to that seen in the chronic laminitic hoof, and often lameness^{6,7}. The increased forces placed on the DDFT from this type of trimming will also promote further hoof capsule distortion and abnormal loading. Furthermore, if there is pathology present in the soft tissue structures of the palmar foot, decreasing the height of the heels will likely place more strain in this section of the foot.

Applying farriery

Distinguishing between a foot with a steep hoof angle and a true club foot is important. High hoof angles without phalangeal misalignment or with mild phalangeal misalignment can generally be managed by adhering to good farriery guidelines for trimming such as using the hoof-pastern axis, the center of rotation and trimming the heels of the hoof capsule to include the frog⁸. In horses with a high hoof angle or mild phalangeal misalignment the heels can be trimmed gradually in a tapered fashion from the apex of the frog to the base of the frog. This increases the ground surface of the foot, preserves the sole and attempts to re-establish weight-bearing on the entire solar surface of the foot. Breakover is moved palmarly at the same time to compensate for any increased tension in the DDFT created by trimming the heels. Breakover can be accomplished by rolling, rockering or grinding breakover into the toe of the shoe. If improvement is noted, the horse should be trimmed/shod in this manner at 4-week intervals.

Farriery to correct a high hoof angle accompanied by a flexural deformity (club foot) becomes more of a challenge. Again, the object of farriery is to load the heels, compensate for the shortening of the deep digital flexor tendon and improve the hoof-pastern axis. To accomplish these objectives, farriery is directed at trimming the heels of the hoof capsule, but the amount of heel to remove can be difficult to



Figure 4. A wedge pad can be placed under the toe of a horse with a club foot which will test the response when tension is exerted on the DDFT. The farrier can then determine the amount of hoof wall that can be safely removed from the heels of the hoof capsule.

determine. In mild to moderate club feet, an estimate of how much heel to remove can be made by placing the thick end of a 2° or 3° degree wedge pad under the toe of the foot and allowing the horse to stand on it (Bob Pethick, CJF – Personal communication) (Figure 4). If the horse does not resent the tension this places on the DDFT, this test allows the farrier to safely trim the hoof wall at the heels in a tapered fashion starting in a palmar direction from the widest part of the foot using the thickness of the degree pad as a guide. The toe is shortened by trimming the outer surface of the dorsal hoof wall with a rasp. The trimmed foot is fitted with a shoe that has the breakover forged or ground into it starting just dorsal to the apex of the frog and tapering toward the toe to further decrease the stresses on the

DDFT. There are also commercial shoes such as the Kerckhaert ‘Comfort’ shoe available that have a rolled toe that provide appropriate breakover. With the more advanced cases of club feet, the heels should still be trimmed to load the heels and unload the toe, but the addition of heel elevation following the trim is necessary to compensate for the shortening of the musculotendinous unit. The

concept of lowering the heels of the hoof capsule with the trim and then adding heel elevation to raise the palmar aspect of the hoof is often not understood. When the heels are trimmed back to the widest part of the frog or to the same plane of the frog, the load bearing surface area of the foot increases palmarly and this is necessary for normal function and loading of the hoof. However, after trimming the heels, the shortened

The amount of heel elevation needed if necessary can be determined following the trim by placing the trimmed foot on the ground 6-8 inches palmar to the contralateral limb. A space will generally be present between the heels of the foot and the ground (Figure 5). I use either a wedge shoe or a shoe with degree pad or a bar wedge between the heels of the foot and the shoe to compensate for the shortening of the muscle-tendon unit (Figure

6a & 6b). This method allows the heels to be weight-bearing but at the same time decreases the stresses on the musculotendinous unit. Creating breakover in the shoe to further relieve stress in the DDFT, as described above, is essential. It is important to note that when the heels are elevated with a wedge shoe, the normal ground reaction forces and load bearing structures are altered due to the height of

the shoe. To redistribute the load on the ground surface of the foot, it is beneficial to apply a “pour-in” pad or a pad with impression material between the branches of the shoe. Following the farriery, the horse will have a flat or mild heel first strike pattern rather than a toe first landing. If the horse does not land flat, additional heel elevation should be considered.

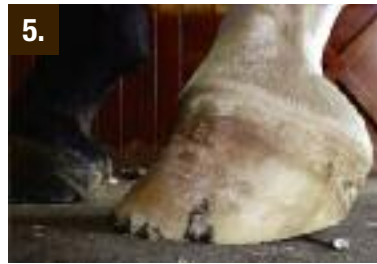

Figure 5. Post trimming, the foot is placed 6-8 inches palmar to the contralateral limb. A space under the heels will indicate shortening of the musculotendinous unit and the necessity of heel elevation.

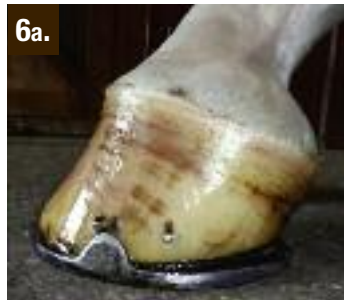

Figure 6a & 6b. Club foot illustrated in Figure 3. Following the appropriate trim, the horse can be shod with heel elevation and a Kerckhaert Steel Comfort - a wide web steel shoe with breakover built into the shoe.

musculotendinous unit must be accommodated and maintained without excessive tension and pain. This is accomplished by decreasing the breakover and by adding elevation to the palmar aspect of the hoof. The degree of wedge that is applied often mimics the amount of heel removed but in many cases may be less due to mechanical contributions made by rocking or rolling the toe of the shoe.

Prepare for Winter with Kerckhaert Snow Rim Pads

Kerckhaert Snow Rim Pads are available in two different materials – rubber in black and polyurethane in clear. Each pair is in an individually wrapped package. Available in large and medium sizes, front and hind.




Liberty LX Nails Available at Marechalerie

The Liberty LX style nail is a hybrid head design similar to the E head but more rectangular in shape. This nail is often used in rim or concave style shoes, as well as European style flat shoes. Farriers across the country are switching to the Liberty nail for the excellent steel quality and consistently sharp points. The highly polished finish and sharp points enable smooth driving and the best end result.



The Bellota Top Sharp Rasp - *Maximum Results*


The aggressive design of the file side lets you get in and get out with maximum results.



Maréchalerie Bromont .Com
OUTILS & ÉQUIPEMENT • SERVICE • TOOLS & EQUIPMENT

Depuis
Since 1990

1-877-267-2759 • info@marechaleriebromont.com



Bobby Menker, CJF
Findaly, Ohio

IN A HURRY BUY!



“I’ve used Vettec’s Adhere product for gluing on shoes for years with great success.”



United States • 600 East Hueneme Road • Oxnard, California 93033 • USA • 1.800.483.8832 • www.vettec.com



THE NATURAL ANGLE is published to provide you with new and useful information about the industry. It is published through a cooperative effort of Vector and Liberty Horseshoe Nails, Bloom Forge, FPD, Kerckhaert Shoes, Vettec, Bellota, Mercury and your supplier.

Articles in this publication are the property of *The Natural Angle* and cannot be reprinted without express permission. For information concerning reprints, please contact Dan Burke, FPD, P.O. Box 1328, Shelbyville, KY 40066 or Email: fpd@farrierproducts.com.

If you have questions, comments or ideas concerning the articles published in the *Natural Angle*, please contact your distributor. We welcome your input. *The Natural Angle* is designed and edited by Graphic Response. ■

Continued from page 4

Conclusion

The club foot is an important cause of hoof capsule distortion, lameness, decreased athletic performance and presents a challenge to the veterinarian and farrier. The clinician must recognize and understand the altered mechanics that are placed on the osseous structures within the hoof, the DIPJ and on the hoof capsule that accompany a flexural deformity involving the DIPJ. This understanding allows the farrier to apply the appropriate farriery and appreciate subsequent improvement.

REFERENCES

1. O'Grady, S.E., Parks, A.H., Redden, R.F., Turner, T.A. (2007) A Glossary of Therapeutic Farriery Terms. *Equine Veterinary Education*, Vol19: 263-271
2. O'Grady SE. Flexural deformities of the distal interphalangeal joint (clubfeet) – a review. *Equine vet Educ* 2012; 24(5) 260-268.
3. Hunt, R.J. (2012) Management of Clubfoot in Horses: Foal to Adult. In *Proceedings. Amer. Assoc of Equine Pract* ;58: 157-163.
4. O'Grady, S.E. (2011) *Farriery for Common Hoof Problems*. In: Baxter GM, ed. *Adams and Stashak's Lameness in Horses 6th ed*. Ames, IA: Wiley-Blackwell. pp 1199-1210.
5. O'Grady, SE, Dryden VC. (2012) Farriery for the horse with the high heel or club foot. In O'Grady, SE, Parks, AH, ed. *The veterinary clinics of North America: Equine Practice* vol. 28:2. Philadelphia: W.B. Saunders, pp 365-380.
6. Turner, T.A. (1992) Inferior Check Desmotomy as a treatment for caudal hoof lameness. *Proceedings, 38th Ann Conv Am Assoc Equine Practn* pp 157-163.
7. Floyd, A.E. Deformities of the Limb and Their Relevance to the Limb. In: Floyd AE, Mansmann, RA., eds. *Equine Podiatry*. St. Louis, MO: Saunders pp 218-223.
8. O'Grady S.E. (2009) Guidelines for Trimming the Equine Foot: A Review. In *Proceedings. Amer. Assoc of Equine Pract* ; 55 pp 218-225.

Dr. Steve O'Grady is a veterinarian and a farrier. He operates Virginia Therapeutic Farriery which is a referral practice devoted to therapeutic farriery located in Marshall, VA.

Disclaimer: Dr. O'Grady has no financial interest in Farrier Products Distribution (FPD) but routinely uses their products in his veterinary practice.

Choose Bellota.

TOP SHARP RASP

CLASSIC RASP

RAZOR RASP

RAPTOR RASP

MINI SHARP RASP

BELLOTA